

Amniotic fluid aspiration in cases of SIDS

Tony Fracasso · Bernd Karger · Mechtild Vennemann ·
Thomas Bajanowski · Ute Maria Golla-Schindler ·
Heidi Pfeiffer

Received: 7 July 2009 / Accepted: 20 October 2009
© Springer-Verlag 2009

Abstract The scope of this study was to evaluate the incidence and the eventual consequences of amniotic fluid aspiration (AFA) in cases of sudden infant death. Cases of sudden infant death syndrome (SIDS; $n=113$: 39 females, 74 males; mean age 4.6 months) were compared to a control group of 39 cases of explained death (14 females, 25 males; mean age 5.6 months). In each case, sections of the lung stained with hematoxylin and eosin and with the immunohistochemical reaction 34BE12 specific for cyto-keratins were available. The microscope slides were observed at $\times 200$ magnification and semi-quantitatively classified into four categories(-, +, ++, and +++). In both groups, rests of amniotic fluid could be observed up to the fourth month of life. The comparison between the two groups did not show any significant difference. In the SIDS group, immunohistochemical reactions with the antibodies CD68, MRP8, MRP14, 27E10, 25F9, CD3, CD20Cy, and CD45R0 were available for the lungs. Twelve cases with

AFA were compared to a group of SIDS cases without AFA with similar age and pathological distribution to evaluate whether the presence of amniotic remnants induced inflammatory changes in the lungs. No differences emerged. This study shows that AFA is not a rare event. Even moderate to severe AFA does not necessary cause death. A correlation between AFA and SIDS could not be shown.

Keywords Amniotic fluid aspiration · Sudden infant death syndrome · Immunohistochemical reactions

Introduction

Amniotic fluid is a solution with 98–99% water and 1–2% soluble and insoluble matter, mainly constituted of proteins, electrolytes, lipids, enzymes, and cellular rests from the fetal skin, urinary, respiratory, and gastrointestinal tract [1–4]. Its aspiration during pregnancy is a paraphysiologic event occurring to the fetus with the intrauterine respiratory movements [5–8]. The perinatal inhalation of meconium- and/or blood-stained amniotic fluid is a life-threatening event requiring intensive care [9, 10]. A severe respiratory distress syndrome was also described after massive inhalation of uncontaminated amniotic fluid. Althoff and Cremer [11] reported an incidence of amniotic fluid aspiration (AFA)-related respiratory distress up to 9%; in a French study [12], the detected incidence was 1.5% with 10% mortality. Moreover, AFA was indicated as potential cause of death in many reports [9, 13–15]. Finally, AFA was also discussed as a potential facilitating factor for subsequent pulmonary inflammation [16–18].

The present study aims at evaluating the prevalence and the eventual pathophysiological meaning of AFA in cases of SIDS compared to controls.

Electronic supplementary material The online version of this article (doi:10.1007/s00414-009-0384-1) contains supplementary material, which is available to authorized users.

T. Fracasso (✉) · B. Karger · M. Vennemann · H. Pfeiffer
Institut für Rechtsmedizin, Universitätsklinikum Münster,
Roentgenstr. 23,
48149 Muenster, Germany
e-mail: Tony.Fracasso@ukmuenster.de

T. Bajanowski
Institut für Rechtsmedizin, Universitätsklinikum Essen,
Muenster, Germany

U. M. Golla-Schindler
Institut für Mineralogie,
Westfälische Wilhelms-Universität Münster,
Muenster, Germany

Materials and methods

Data was obtained from documents collected during the Westphalian Cot Death Study from 1990-1994 [19] and the multi-center German study on sudden infant death syndrome during the period from 1998 until 2001 [20–22]. In the first part of the study, 113 SIDS cases (39 females, 74 males, mean age 4.6 months, median 4 months, min 9 days, max 335 days; females: mean age 5.3 months, median 5 months, min 13 days, max 335 days; males: mean age 4.2 months, median 4 months, min 9 days, max 275 days) were compared with 39 cases of explained death (14 females, 25 males, mean age 5.6 months, median 5 months, min 3 days, max 348 days; females: mean age 6.6 months, median 6 months, min 21 days, max 348 days; males: mean age 5 months, median 4 months, min 3 days, max 310 days). In the SIDS group, precise information about gestational age, weight at birth, and Apgar score at 1, 5, and 10 min were available. The non-SIDS group was constituted of cases in which the cause of death had been clearly identified (Table 1).

Besides routine histological staining with hematoxylin and eosin (H&E) and periodic acid-Schiff (PAS), the immunohistochemical reaction with the high molecular weight antibody 34 β E12 (Novocastra, Newcastle upon Tyne, UK) reacting with cytokeratins 1, 5, 10, and 14 was performed for the lungs. At least two lung sections per case were cut at 4 μ m from paraffin-embedded blocks on Superfrost Plus slides and dried overnight at 60 °C. After deparaffinization and seriate baths in ethanol solutions (once at 100% concentration, twice at 96%, once at 70%, each time for 2-5 min), the samples were incubated for 25 min in a steamer with Target Retrieval Solution (Dako Deutschland GmbH, Hamburg, Germany). After washing with distilled water and tris-buffer, the samples were incubated at 37 °C with proteinase K for 15 min and then incubated overnight at 4 °C with the primary antibody

34 β E12 (1:100 dilution) and, finally, stained in the Autostainer Plus immunostainer (Dako Deutschland GmbH, Hamburg, Germany) with REAL Detection System Peroxidase/AEC Rabbit/Mouse (Dako Deutschland GmbH, Hamburg, Germany). The samples were observed at \times 200 magnification (Axioscope 2, Carl Zeiss MicroImaging GmbH, Jena, Germany, \times 20 objective, and \times 10 ocular) and semi quantitatively classified on the basis of the presence of clumps of squames inside the bronchioles and alveoli. Four categories were distinguished: no AFA (–), minimal (+), moderate (++) , and severe (+++) AFA.

Chi-square test and Student *t* test were performed for statistical analysis by mean of free online software (http://www.aly-abbara.com/utilitaires/statistiques/khi_carre.html; http://www.physics.csbsju.edu/stats/t-test_bulk_form.html).

The same tests were performed to verify the possible correlation between AFA and gestational age, weight at birth, and Apgar score at 1, 5, and 10 min.

In approximately 20% of the cases, independent from the investigated group, the positive reactions occurred in form of a carpet-like patina focally covering the surface of the alveolar spaces made the verification of potential artifacts necessary. For this reason, five cases (two with classical morphology, three with atypical one) were exemplary analyzed with electron microscopy; the positive area was punched from the paraffin block and embedded in epoxy resin according to common protocols (for details, Fig. S1). To verify the quality of the tissue, semifine sections (0.5-1 μ m) were stained with toluidine blue.

Electron microscopy studies were performed with a ZEISS 1540EsB FIB (Carl Zeiss NTS GmbH, Oberkochen, Germany) using the electron beam. The transmission mode was performed with a STEM-UNIT which was accommodated on the scanning electron microscope specimen table. The signal was detected with the conventional SE ETD chamber detector and, therefore, delivers TV-rate images that significantly decrease the contamination due to the short dwell times in comparison to the alternative detection using a semiconductor device [23]. This enables the study of thin sections of lung cells with sufficient contrast and resolution.

In the SIDS group, immunohistochemical reactions with the antibodies CD68, MRP8, MRP14, 27E10, 25F9, CD3, CD20Cy, and CD45R0 (Table 2) were available for the lungs. Twelve cases with AFA were compared to a group of SIDS cases without AFA with a similar age and pathological distribution to evaluate whether the presence of amniotic remnants induced inflammatory changes in the lungs. In each case, two slides were evaluated. Per slide, seven fields at \times 200 magnification (Axioscope 2, Carl Zeiss MicroImaging GmbH, Jena, Germany, \times 20 objective, and \times 10 ocular) were randomly considered. The mean number of the positive interstitial, alveolar, bronchial, and intravascular macrophages as well as the mean number of the

Table 1 Control group

Cause of death	Number of cases
Respiratory infection	13
Sepsis	4
Dehydration	4
Asphyxia	4
Cerebral hemorrhage	3
Traumatic brain injury	2
Myocarditis	2
Pyelonephritis	2
Systemic cytomegalovirus infection	2
Hirschprung's disease	1
Ileus	1
Carrot juice embolism after intravenous injection	1

Table 2 Antibodies used to verify the inflammatory population in the lungs

Antibody	Producer	Cell population
CD68	Dako Deutschland GmbH, Hamburg, Germany	Macrophages, general marker
MRP8	BMA Biomedicals, Augst, Switzerland	Macrophages, late stage marker
MRP14	BMA Biomedicals, Augst, Switzerland	Macrophages, acute stage marker
27E10	BMA Biomedicals, Augst, Switzerland	Macrophages, acute inflammation, early stage
25F9	BMA Biomedicals, Augst, Switzerland	Macrophages, chronic inflammation, late stage
CD3	Dako Deutschland GmbH, Hamburg, Germany	T cells
CD20cy	Dako Deutschland GmbH, Hamburg, Germany	B cells
CD45R0	Dako Deutschland GmbH, Hamburg, Germany	Activated-T cells

intravascular and interstitial lymphocytes was registered and compared in the two subgroups. Student's *t* test was performed for statistical analysis.

Results

In the SIDS group, 96 cases (85%) did not show AFA. In 17 (17.7%) cases, AFA could be diagnosed [(+): *n*=9 (8%); (++): *n*=7 (6.2%); and (+++): *n*=1 (0.9%)]. In the control group, 32 cases did not show AFA (82.1%). The seven positive cases (18%) were distributed as follows: (+): *n*=2 (5.1%), (++): *n*=2 (5.1%), (+++): *n*=3 (7.7%). The chi-square test did not show any significant difference between the groups. The frequency of AFA in the different groups is depicted in Table 3. The electron microscopy findings confirmed the suspicion that the positive areas showing the unusual carpet-like morphology were artifacts (Fig. 1a-d).

Rests of amniotic fluid could be detected up to the age of 4 months in both groups. Considering all the investigated cases as a single group, the distribution of the positive cases in the first 4 months show a statistically significant decrease month after month (first month: 63.6%, second month: 31.8%, third month: 17.9%, and fourth month: 16.7%).

In the SIDS group, cases with and without AFA did not show any differences in relation to gestational age, weight at birth, and Apgar at 1, 5, and 10 min.

Concerning the evaluation of the inflammatory reaction, AFA positive cases of SIDS did not show any increased inflammatory activity compared with SIDS cases without AFA. These two groups also showed a similar composition with regard to the others investigated

parameters (gestational age, weight at birth, and Apgar at 1, 5, and 10 min).

Discussion

The histological evaluation of the lung of the newborn and the infant in the first weeks/months of life is a difficult task that requires experience. The typical infant lung shows areas of atelectasia beside well ventilated alveoli. The interstitial space seems thick and the general impression is that of a cell-rich organ. Clumps of squames can be observed in the alveoli. If they are numerous, part of the lung is usually atelectasic and the identification with simple H&E or PAS staining may be difficult for the occasional investigator. A better identification is achieved with immunohistochemistry. The monoclonal antibody applied in this study has given a satisfactory and very easy identification of the positive structures; in approximately 20% of the cases, it is characterized by artifacts (Fig. 1c) whose morphology is different from typical rests of amniotic fluid (Fig. 1a), thus, not leading to confusion. In a precursor study, we had not recognized this morphology as due to artifacts [24]. According to the manufacturer, false positivity may be due to necrotic or degenerated cells; the random coloration of some pneumocytes is also reported.

Deaths related to amniotic fluid are a classical task in legal medicine and are represented, from one side, by cases of embolism through uterine veins during labor and delivery [25, 26] and, from the other side, by its possible aspiration in the airways of the newborn during delivery [27, 28]. The aspiration of uncontaminated amniotic fluid has been repeatedly reported to be potentially lethal [9, 13, 14]. To explain this lethality, three pathophysiological mechanisms have been proposed: the obstruction of the airways with atelectasis of the lung parenchyma and terminal asphyxia [9], the increase of lung water with subsequent surfactant washout [8], and the generation of thrombin and proaggregatory thromboxane A2 leading to pulmonary hypertension [29].

Table 3 Distribution of AFA in the investigated groups

Group	-	+	++	+++
SIDS	83.6%	7.8%	7%	1.6%
Control	78.8%	12.1%	3%	6%

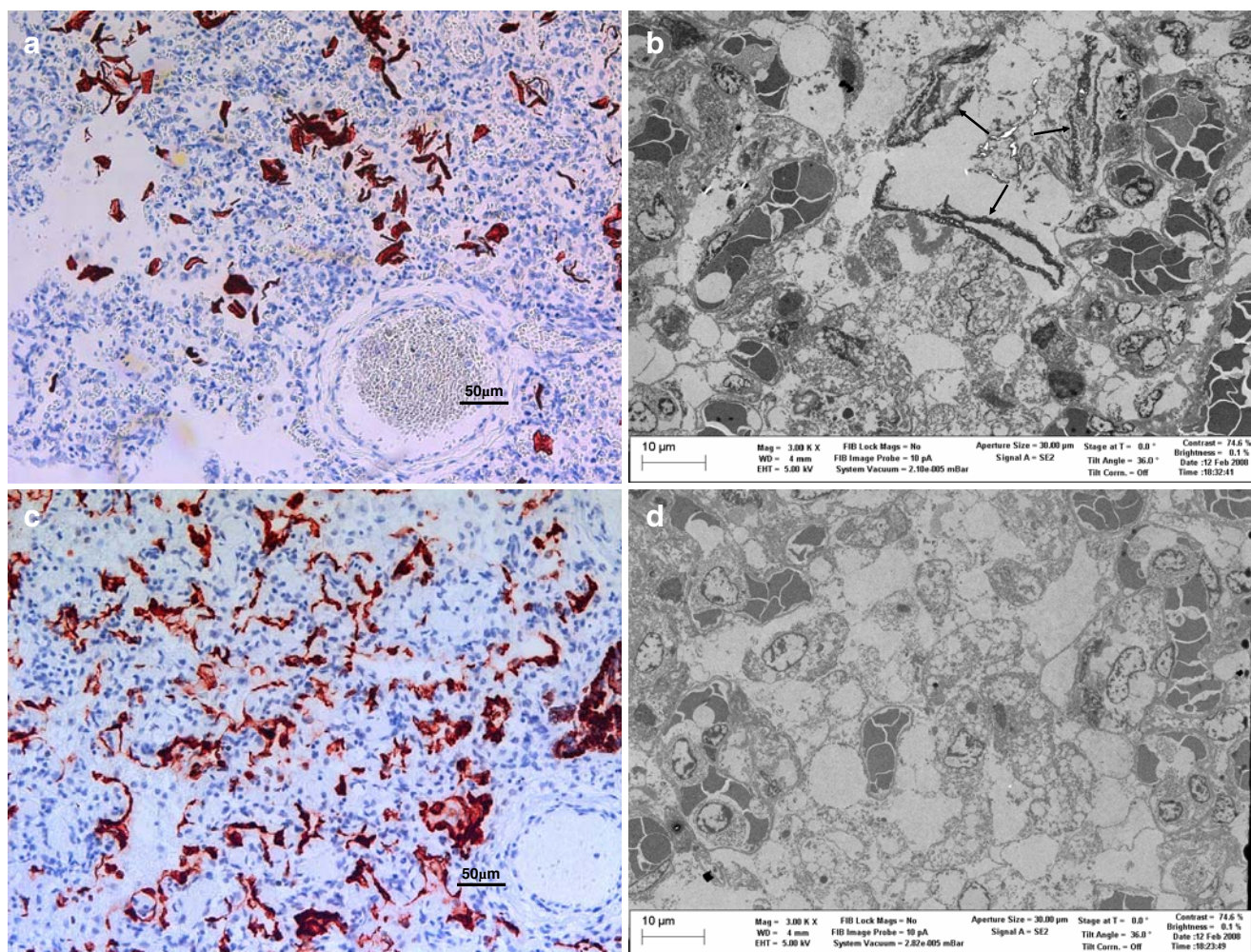


Fig. 1 **a** Severe AFA with atelectasis. The epithelial fragments are here depicted in their classical morphology (immunohistochemical reaction, 34 β E12, \times 200). **b** The electron microscopy in the same case confirmed the presence of epithelial rests in the alveoli (Zeiss 1540EsB FIB, \times 3,000). **c** Atypical morphology: positive reactions in

form of a carpet-like patina covering the surface of the alveolar spaces (immunohistochemical reaction, 34 β E12, \times 200). **d** The electron microscopy in the same case showed the absence of epithelial rests, thus, confirming the hypothesis of artifacts (Zeiss 1540EsB FIB, \times 3,000)

In this study, AFA was detected up to 4 months of age in both investigated groups, while severe AFA could only be observed during the first month of life in both groups. A late detection of rests of amniotic fluid at the age of 2.5 months was reported by Caroff and Celestin [6]. It is possible that the application of immunohistochemistry in our cases facilitated the detection of minimal remnants which could have been otherwise not identified at common histology. A physiologic process of phagocytosis through the normal resident macrophage population is the probable reason for the decreasing detection of amniotic fluid rests with increasing age.

In all our cases, AFA was an accessory finding without correlation with the cause of death. Moreover, no differences were found between SIDS and controls concerning the frequency and the grade of AFA;

therefore, the occurrence of AFA does not seem to correlate with SIDS.

The investigation on the potential role of AFA as a trigger of pulmonary inflammation has demonstrated comparable and normal leukocyte distribution in the investigated cases, thus, supporting the hypothesis that the aspiration of uncontaminated AF does not lead to local inflammation of the pulmonary tissue.

In isolated cases, it may be possible that massive AFA results in death. This is, however, an exceptional event that may mostly occur in a short period after birth (hours to a few days) and should be preceded by clinical evidence of distress. The longer the time between birth and death, the lower the possibility that the fatal event has a correlation with AFA especially in absence of a continuous pathological clinical history

from birth. In the vast majority of the cases in which AFA is histologically diagnosed, it is an accessory finding without pathological relevance.

References

- Sozanskii AM (1961) The biochemical composition of amniotic fluid of maternal and fetal blood at various periods of pregnancy. *Bull Exp Biol Med* 3:323–326
- Bonsnes RW (1966) Composition of amniotic fluid. *Clin Obst Gynecol* 9:440–448
- Fuchs F (1966) Volume of amniotic fluid at various stages of pregnancy. *Clin Obst Gynecol* 9:449–460
- Jalanko H, Rapola J, Lehtonen E (1985) Particulate fraction in amniotic fluid at second trimester. *J Clin Pathol* 38:1065–1072
- Colebatch HJH, Halmagyi DFJ, Starzecki B (1963) Effect of amniotic fluid aspiration on the lung and circulation. *Pediatrics* 32:808–815
- Caroff J, Celestin E (1973) Neonatal and still-birth problems: the forensic point of view. Intrauterine submersion. *For Sci* 2:459–465
- Duenholter JH, Pritchard JA (1977) Fetal respiration. *Am J Obstet Gynecol* 129:326–338
- Jose JH, Schreiner RL, Lemons JA, Gresham L, Mirkin LD, Siddiqui A, Cohen M (1983) The effect of amniotic fluid aspiration on pulmonary function in the adult and newborn rabbit. *Ped Res* 17:976–981
- Pender CB (1973) Respiratory distress in the newborn due to aspiration of amniotic fluid and its contents. *Resuscitation* 2:157–167
- Hermansen CL, Lorah KN (2007) Respiratory distress in the newborn. *Am Fam Physician* 76:987–994
- Althoff H, Cremer U (1989) Arztrechtliche und morphologische Aspekte einer tödlichen Fruchtwasserapiration. *Z Rechtsmed* 102:11–23
- Cottancin G, Bourgeois J, Cordier M-P, Bethenod M (1980) L'inhalation amniotique. A propos de 225 observations. *Pediatric* 35:105–117
- Ikeda N, Yamakawa M, Imai Y, Suzuki T (1989) Sudden infant death from atelectasis due to amniotic fluid aspiration. *Am J For Med Pathol* 10:340–343
- Bolisetty S, Patole SK, McBride GA, Whitehall JS (2001) Neonatal amniotic fluid aspiration syndrome underdiagnosed? *Int J Clin Pract* 55:727–728
- Laberke PJ, Deubler G (2009) Sudden intrauterine death associated with furcate insertion of the umbilical cord. *Int J Legal Med*. doi:10.1007/s00414-008-0295-6
- Camerer J (1938) Beiträge zur frage der fruchtwasserapiration. *Z ges Gerichtl Medizin* 29:333–346
- Vidal MT, Moragas A (1981) Alveolar exudation versus leukocyte aspiration in congenital pneumonia. *Pathol Res Pract* 173:22–29
- Liu YL, Lin LM, Zhu J, Zhang ZJ, Li Z (1991) Case-control study on pathogenesis of pneumonia in children aged 0–2 years. *Chin Med J* 104:22–26
- Jorch G, Schmidt-Troschke S, Bajanowski T, Heinecke A, Findeisen M, Nowack C, Rabe G, Freislederer A, Brinkmann B, Harms E (1994) Epidemiologische Risikofaktoren des plötzlichen Kindstodes. Ergebnisse der westfälischen Kindstodsstudie 1990–1992. *M Schr Kinderheilkd* 142:45–51
- Findeisen M, Vennemann MM, Brinkmann B, Ortman C, Röse I, Köpfke W, Jorch G, Bajanowski T (2004) German Study on Sudden Infant Death (GeSID): design. Epidemiological and pathological profile. *Int J Legal Med* 118:163–169
- Bajanowski T, Brinkmann B, Vennemann M (2006) The San Diego definition of SIDS: practical application and comparison with the GeSID classification. *Int J Legal Med* 120:331–336
- Schlaud M, Dreier M, Debertin AS, Jachau K, Heide S, Giebe B, Poets SJP, CF KWJ (2009) The German case-control scene investigation study on SIDS: epidemiological approach and main results. *Int J Legal Med*. doi:10.1007/s00414-009-0317-z
- Golla-Schindler U (2004) STEM-Unit measurements in a scanning electron microscope. Proceedings of the 13th European Microscopy Congress. Antwerpen Vol. I 409–410
- Karger B, Fracasso T, Bajanowski T, Ortmann C, Brinkmann B (2005) Amniotic fluid aspiration—immunohistochemical study of 164 autopsy cases. Sixth International Symposium on Advances in Legal Medicine (ISALM). Hamburg 19–24 Sept 2005. Abstract in: *Rechtsmedizin* 4:267
- Christiansen LR, Collins KA (2006) Pregnancy-associated deaths: a 15-year retrospective study and overall review of maternal pathophysiology. *Am J Forensic Med Pathol* 27:11–19
- Sinicina I, Pankratz H, Bise K, Metevossian E (2009) Forensic aspect of post-mortem histological detection of amniotic fluid embolism. *Int J Legal Med*. doi:10.1007/s00414-009-0351-x
- Hartmann G, Mueller B (1975) Natürlicher Tod des Kindes in der Zeit von Geburt, während der Geburt und kurz nach der Geburt, einschliesslich geburts-traumatischer Schädigungen (perinatale kindliche Sterblichkeit). In: Mueller B (ed) *Gerichtliche Medizin*, Band 2. Springer-Verlag, Berlin, Heidelberg, pp 1133–1139
- Janssen W (1984) Pregnancy, abortion, aborticide. The problem of the cause of death. In: Janssen W (ed) *Forensic histopathology*. Springer-Verlag, Berlin, pp 205–207
- Stuart M, Wu J, Sunderji S, Ganley C (1987) Effect of amniotic fluid on platelet thromboxane production. *J Pediatr* 110:289–292