




Official Journal of the European Paediatric Neurology Society



## Case study

# Episodic ataxia type 2 showing ictal hyperhidrosis with hypothermia and interictal chronic diarrhea due to a novel CACNA1A mutation

D.I. Zafeiriou<sup>a,\*</sup>, F. Lehmann-Horn<sup>b</sup>, E. Vargiami<sup>a</sup>, E. Teflioudi<sup>a</sup>,  
A. Ververi<sup>a</sup>, K. Jurkat-Rott<sup>b,\*</sup>

<sup>a</sup>1st Department of Pediatrics, Aristotle University of Thessaloniki, Egnatia St. 106, 54622 Thessaloniki, Greece

<sup>b</sup>Department of Applied Physiology, University of Ulm, Germany

## ARTICLE INFO

## Article history:

Received 11 December 2007

Received in revised form

15 February 2008

Accepted 17 February 2008

## Keywords:

Episodic ataxia type 2

CACNA1A gene

Acetazolamide

Migraine

Diarrhea

Hyperhidrosis

## ABSTRACT

Autosomal dominant episodic ataxia type 2 (EA2) results from mutations of the CACNA1A gene. We describe EA2 with unusual features in a father and daughter with a novel CACNA1A mutation coding for Y248C. Both patients showed severe cerebellar atrophy in MRI and clinical signs of progressive spinocerebellar atrophy type 6. Most disabling were the very frequent episodes of ataxia with migraine (with aura in the father and without aura in the daughter) and nystagmus in our patients. Additionally, they suffered from ictal hyperhidrosis with acute hypothermia of the extremities. Lastly, the father presented with interictal chronic diarrhea not associated to a known primary gastrointestinal disorder. Both ictal hyperhidrosis and interictal diarrhea ameliorated upon acetazolamide intake, the typical treatment for EA2. The significance of these findings is discussed and the phenotype correlated to previously reported cases.

© 2008 European Paediatric Neurology Society. Published by Elsevier Ltd. All rights reserved.

## 1. Introduction

Episodic ataxia type 2 (EA2) is an autosomal dominant disorder characterized by paroxysmal ataxia and interictal nystagmus. The paroxysmal ataxia attacks may be accompanied by vertigo, nausea, dysarthria, diplopia, tinnitus, dystonia, hemiplegia, and headache. Attacks can be triggered by stress, exertion, caffeine, alcohol, and phenytoin and relieved by acetazolamide. During the interictal period, patients may initially be asymptomatic, but eventually develop limb ataxia, postural imbalance, myasthenia-like weakness, and interictal

gaze-evoked or downbeat nystagmus. Cerebellar atrophy with progressive ataxia and forms of migraine are frequently present in EA2.<sup>1,2</sup>

EA2 arises from mutations in the alpha 1A-subunit of the brain P/Q-type calcium channel, Cav2.1, encoded by the CACNA1A gene on chromosome 19p13.<sup>3</sup> EA2 mutations mainly result in premature truncations, however, missense mutations have been described. Two allelic disorders with phenotypic overlaps are hemiplegic migraine caused by Cav2.1 missense mutations<sup>3</sup> and spinocerebellar ataxia type 6 (SCA6) caused by a polyglutamine expansion in the channel

\* Corresponding authors. Tel.: +30 2310 241845; fax: +30 23920 63186.

E-mail address: jeff@med.auth.gr (D.I. Zafeiriou).

1090-3798/\$ – see front matter © 2008 European Paediatric Neurology Society. Published by Elsevier Ltd. All rights reserved.

doi:10.1016/j.ejpn.2008.02.011

carboxy terminus.<sup>4</sup> We describe the clinical and genetic features of two related patients with EA2 sharing a novel mutation of the CACNA1A gene.

## 2. Case report

Our patients, a 7-year old daughter and her 35-year old father were identified through a neurodevelopmental clinic. EA2 manifested at first and third year of life, respectively.

Ictal symptoms in both cases consisted of recurrent episodes of cerebellar ataxia accompanied by spontaneous horizontal gaze-evoked nystagmus and migraine headache, occasionally triggered by physical stress (i.e. sleep deprivation) or emotional stress. The ictal migraine of the father additionally showed facial hypoesthesia and left-sided hemiplegia especially of the upper extremity. Both patients had ictal hyperhidrosis of the face and the extremities (especially of the arms) which led to acute hypothermia of the extremities with temperatures down to 35.5 °C, however without signs of cold-induced vasoconstriction (i.e. blue nails of fingers and toes or signs of atrophy in the fingertips). The hyperhidrosis was present for almost the whole duration of these episodes, while heart rate and blood pressure were at the upper normal limit for age. These episodes lasted 8–10 h, occurred every 2–3 weeks, and were resolved by sleep in both patients without ever evolving to delirium or unconsciousness. None of the patients had ictal vertigo, brainstem symptomatology or other extracerebellar signs.

Interictally, both patients reported typical episodes of pure migraine according to the IHS criteria: migraine with aura in the father (mean frequency of the attacks twice a month with a mean duration of 2 h) and simple migraine without aura in the daughter (mean frequency once a month with a mean duration of 1.5 h), which were unresponsive to paracetamol or mephenamic acid and resolved only after vomiting or falling asleep. There was a significant overlap to the SCA6 phenotype both morphologically, with severe cerebellar atrophy in cranial MRI (Fig. 1) and clinically (mild baseline nystagmus and mild slowly progressive baseline trunk ataxia without

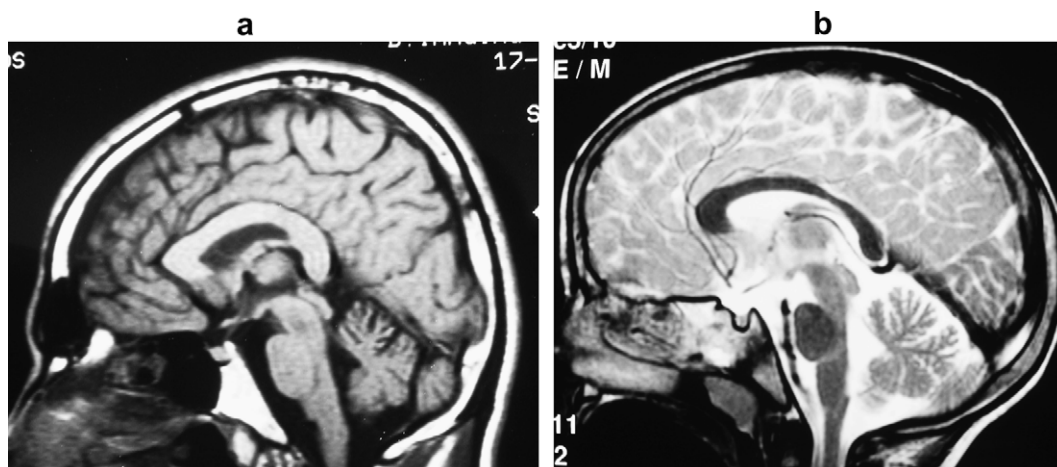
fluctuations). The father also suffered from interictal chronic abdominal cramping pain and diarrhea with liquid excrements almost 2–3 times a day, which were not caused by a primary gastrointestinal disorder (i.e. Morbus Crohn and colitis ulcerosa), which was excluded.

Genomic DNA was isolated from peripheral blood with patients' informed consent and CACNA1A was analyzed for mutations. In exon 5, a novel base change, A743G (Fig. 2), coding for Y248C at the junction of S5 and the pore loop of domain I of Cav2.1, was identified in both patients but not in the unaffected mother. The amino acid substitution was not present in 149 control samples and is conserved all the Cav2 family, i.e. Cav2.1, Cav2.2, and Cav2.3, in human, mouse, and rabbit species. Testing for the CAG elongation coding for the polyglutamine expansion responsible for SCA6 was negative (R Christodoulou, Institute of Genetics, Cyprus).

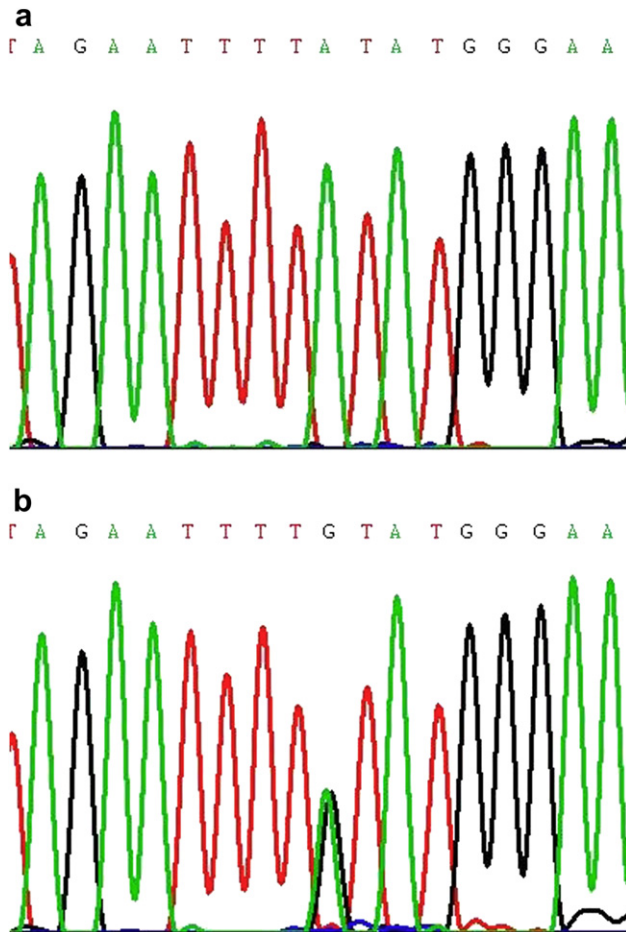
Acetazolamide was given to the daughter in a dose of 250 mg/d and to the father in a dose of 500 mg/d. This treatment reduced the frequency of attacks by more than 75% (follow-up period 15 months), with a simultaneous decrease of the severity and duration of the attacks; there were no more episodes of hemiplegic migraine in the father, while the daughter experienced a decrease in her migraine attacks as well. Additionally, under treatment, the hyperhidrosis disappeared completely in both father and daughter. Lastly, acetazolamide decreased the frequency of diarrhea in the father from 2.7 times per day to once every 3 weeks in the 6 months follow-up period.

## 3. Discussion

Y248C fulfills several criteria for a causative mutation, i.e. it is not present in a large number of controls and it affects a highly conserved residue in a channel known to be related to EA2. In contrast to the majority of EA2 mutations which are nonsense mutations, Y248C codes for a single amino acid exchange. However, Y248C shares the association to the pore loop of domain I just like the Cav2.1 missense mutations H253Y, C271Y, and G293R all of which cause EA2 also.<sup>5–7</sup> Like C271Y and G293R,<sup>6,7</sup> Y248C shows prominent cerebellar atrophy and



**Fig. 1 – MRI of 7-year-old daughter (a) and 37-year-old father (b) demonstrating atrophy of the cerebellar vermis (predominately the anterior part) on T2-weighted imaging corresponding to the clinical SCA6-like phenotype.**



**Fig. 2 – Sequence of exon 5 around base A743 in control (a: top) and patient (b: bottom). Note the A-to-G base change in the patient which changes the triplet TAT to TGT coding for a tyrosine to cysteine at position 248.**

SCA6-like symptoms even at the very young age of 7 years. Therefore, the functional defect of Y248C may be similar to that of C271Y and G293R which showed reduced Cav2.1 expression due to deficient channel membrane targeting, and evidence of protein misfolding leading to reduced channel function.<sup>6</sup> We conclude that the outermost amino acid residue of S5, Y248, may contribute to the orientation of the pore loop of domain I, and that the reduction of channel conductance and channel trafficking together accelerates cerebellar atrophy. Therefore, the Cav2.1 pore mutations including Y248C differ clearly from the many Cav2.1 nonsense mutations leading to a loss-of-function EA2 pathomechanism by haploinsufficiency only.

The phenotype in our patients differs from previous reports by two features. One is the ictal hyperhidrosis with hypothermia. While the presence of Cav2.1 channels in

sudomotoric synapses has not been demonstrated yet, these sympathetic synapses are of the subthreshold kind<sup>8</sup> similar synapses of which do express Cav2.1.<sup>9</sup> The fixed association of hyperhidrosis with the EA2 attacks and the improvement by EA2 medication, acetazolamide, strengthen a possible association between Y248C and this symptom. The second feature that is different in our patients is the interictal diarrhea. As the mechanism for neurotransmitter release of acetylcholine in gastrointestinal submucosal neurons requires Cav2.1,<sup>10</sup> it is thinkable that diarrhea may be associated with the Cav2.1 mutation Y248C as well. This hypothesis is supported by the lack of other explanation for the diarrhea and the observation that the symptoms improved under acetazolamide treatment, the classic EA2 therapy. We recommend to examine the presence of these symptoms in EA2 patients and, if present, to try acetazolamide for relief.

#### REFERENCES

1. Jen JC, Kim GW, Baloh RW. Clinical spectrum of episodic ataxia type. *Neurology* 2004;**62**:17–22.
2. Jen JC, Graves TD, Hess EJ, Hanna MG, Griggs RC, Baloh RW, CINCH investigators. Primary episodic ataxias: diagnosis, pathogenesis and treatment. *Brain* 2007;**130**:2484–93.
3. Ophoff RA, Terwindt GM, Vergouwe MN, van Eijk R, Oefner PJ, Hoffman SM, et al. Familial hemiplegic migraine and episodic ataxia type-2 are caused by mutations in the Ca<sup>2+</sup> channel gene CACNL1A4. *Cell* 1996;**87**:543–52.
4. Zhuchenko O, Bailey J, Bonnen P, Ashizawa T, Stockton DW, Amos C, et al. Autosomal dominant cerebellar ataxia (SCA6) associated with small polyglutamine expansions in the alpha(1A)-voltage-dependent calcium channel. *Nature Genet* 1997;**15**:62–9.
5. van den Maagdenberg A, Kors E, Brunt E, van Paesschen W, Pascual J, Ravine D, et al. Episodic ataxia type 2. Three novel truncating mutations and one novel missense mutation in the CACNA1A gene. *J Neurol* 2002;**249**:1515–9.
6. Wan J, Khanna R, Sandusky M, Papazian D, Jen J, Baloh R. CACNA1A mutations causing episodic and progressive ataxia alter channel trafficking and kinetics. *Neurology* 2005;**64**:2090–7.
7. Yue Q, Jen J, Nelson S, Baloh R. Progressive ataxia due to a missense mutation in a calcium-channel gene. *Am J Hum Genet* 1997;**61**:1078–87.
8. Ogawa T. Subthreshold sudomotor nerve impulses for general sweating in cool environment. *Tohoku J Exp Med* 1970;**100**:255–61.
9. Ireland DR, Davies PJ, McLachlan EM. Calcium channel subtypes differ at two types of cholinergic synapse in lumbar sympathetic neurones of guinea-pigs. *J Physiol* 1999;**514**:59–69.
10. Cunningham SM, Mihara S, Higashi H. Presynaptic calcium channels mediating synaptic transmission in submucosal neurones of the guinea-pig caecum. *J Physiol* 1998;**509**(Pt 2): 425–35.