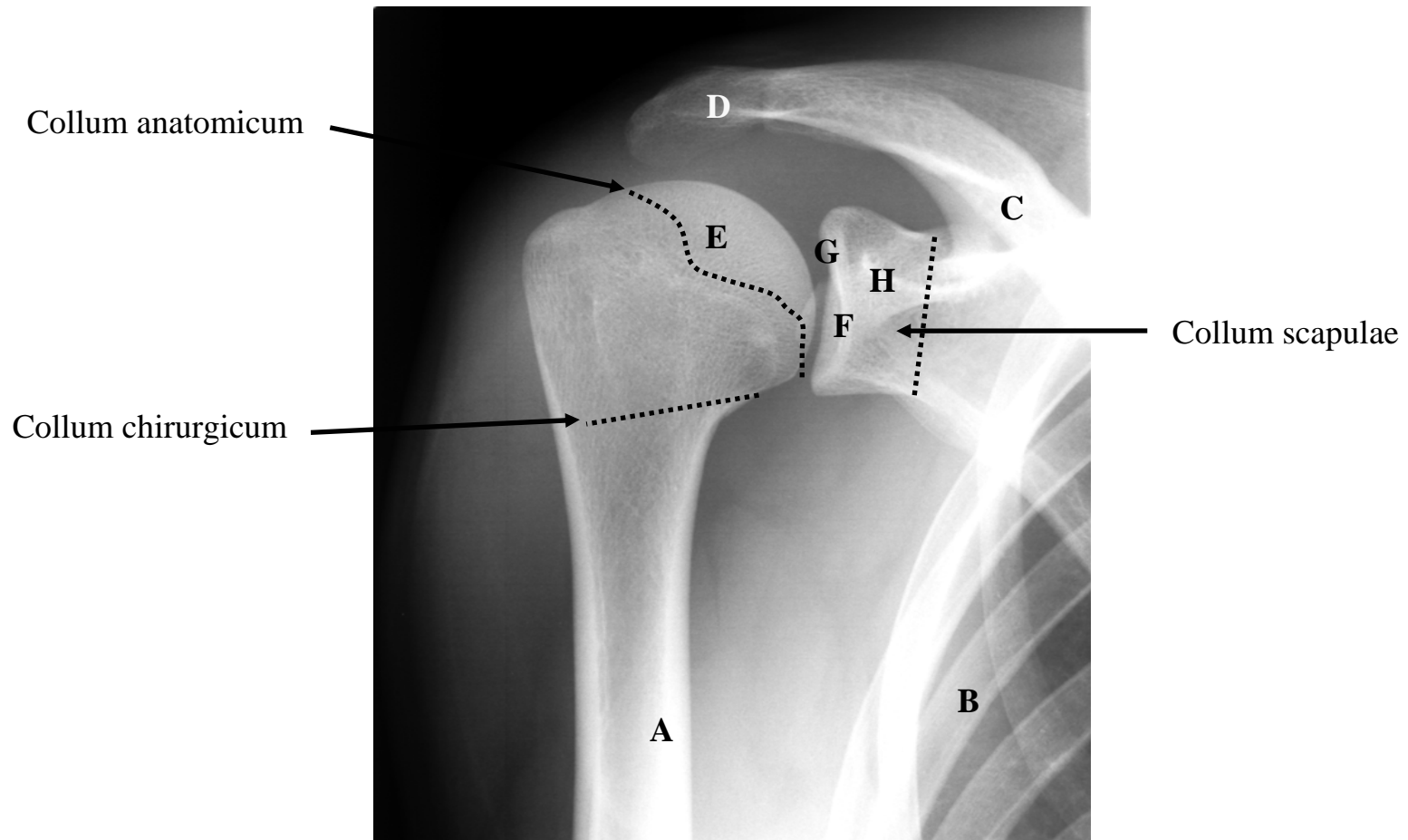


# Röntgenaufnahme a.p., rechtes Schultergelenk



A Humerus, Schaft  
B Costa  
C Clavicula  
D Acromion  
E Caput humeri

F Cavitas glenoidalis  
G Gelenkspalt  
H Processus coracoideus  
(hinter collum scapulae)