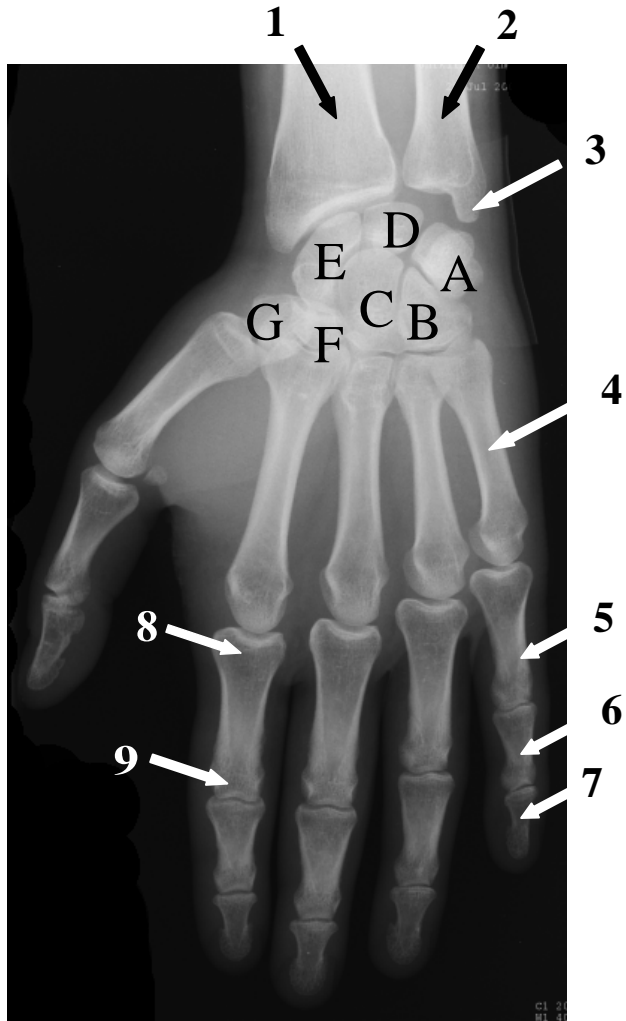


Röntgenaufnahme, linke Hand, dorso-volar



- | | | |
|------------------------------|-------------------------------|---------|
| A: Os trigetum, os pisiforme | 1: Radius; | 2: Ulna |
| B: Os hamatum | 3: Processus styloideus ulnae | |
| C: Os capitatum | 4: Os metacarpale V | |
| D: Os lunatum | 5: Phalanx proximalis V | |
| E: Os scaphoideum | 6: Phalanx medialis V | |
| F: Os trapezoideum | 7: Phalanx distalis V | |
| G: Os trapezium | 8: Basis phalangis prox. II | |
| | 9: Caput phalangis prox. II | |

Angiographie

