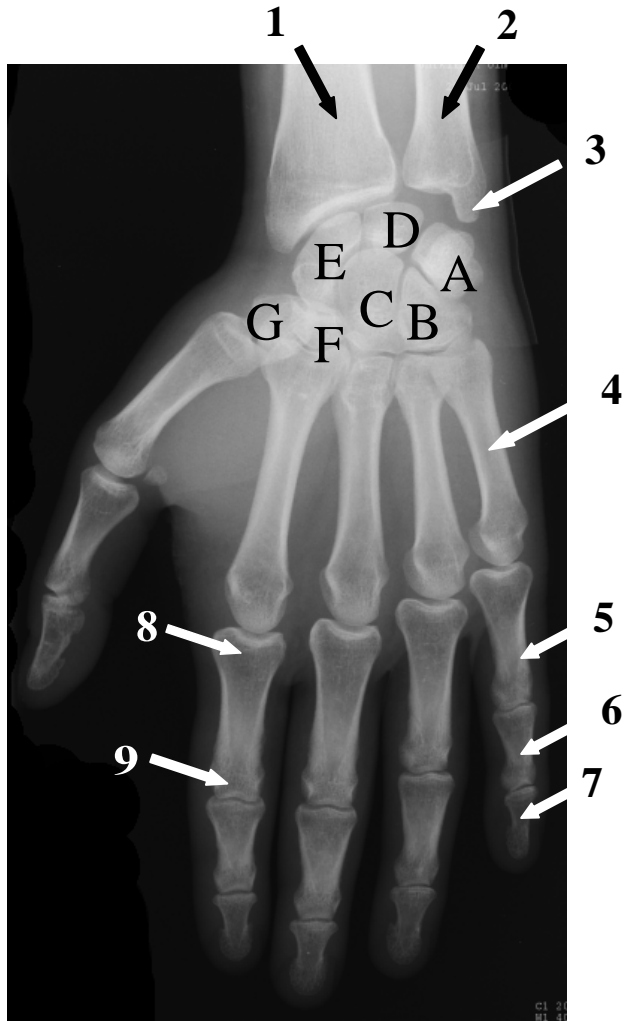


Röntgenaufnahme,
linke Hand, dorso-volar



Angiographie

