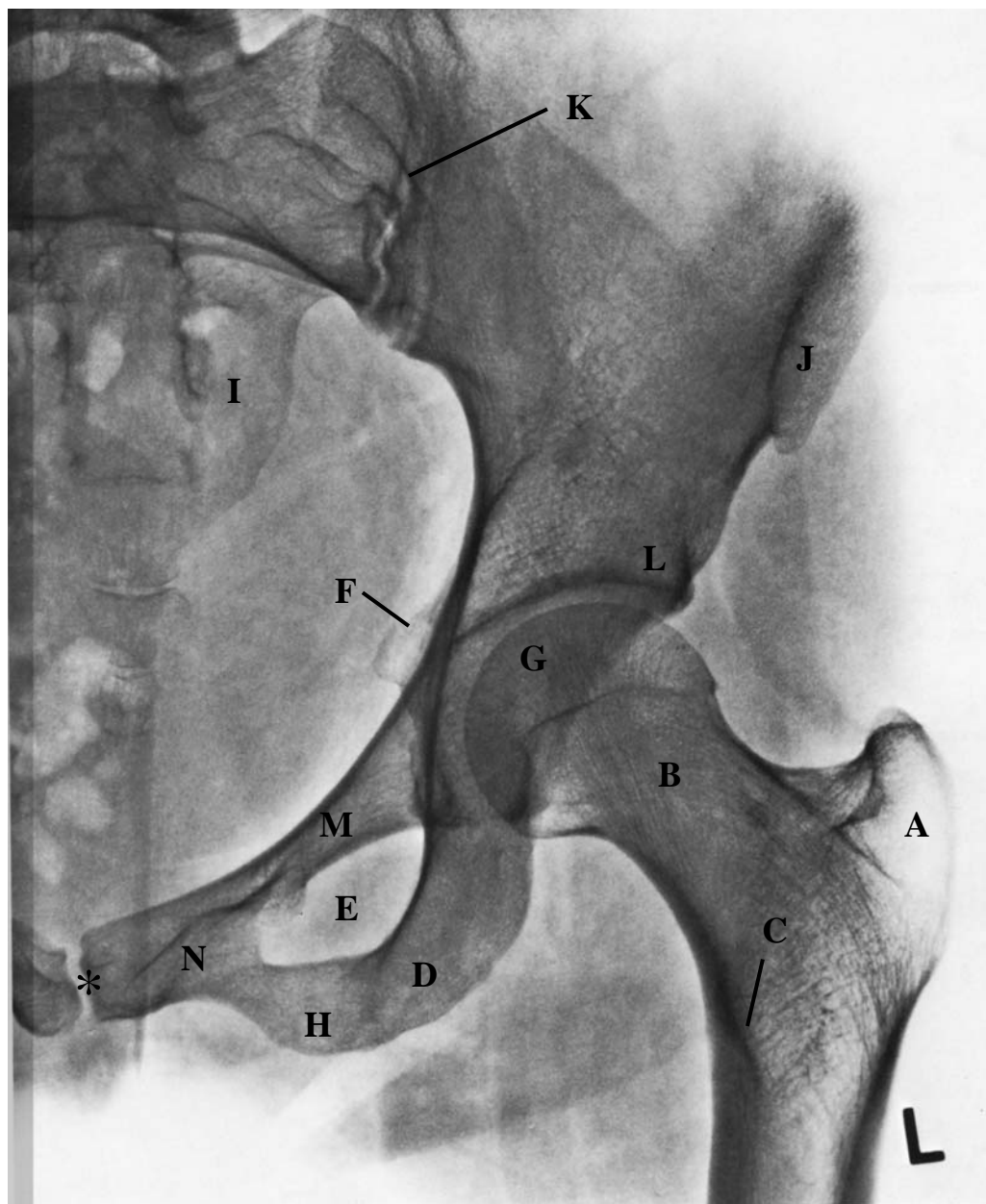


# Röntgenaufnahme a.p., linke Hüfte



\* Symphyse

- |                     |                            |
|---------------------|----------------------------|
| A Trochanter major  | H Ramus inf. ossis pubis   |
| B Collum femoris    | I Os sacrum                |
| C Trochanter minor  | J Spina iliaca ant. sup.   |
| D Tuber ischiadicum | K Articulatio sacro-iliaca |
| E Foramen obturatum | L Limbus acetabuli         |
| F Spina ischiadica  | M Ramus sup. ossis pubis   |
| G Caput femoris     | N Os pubis                 |