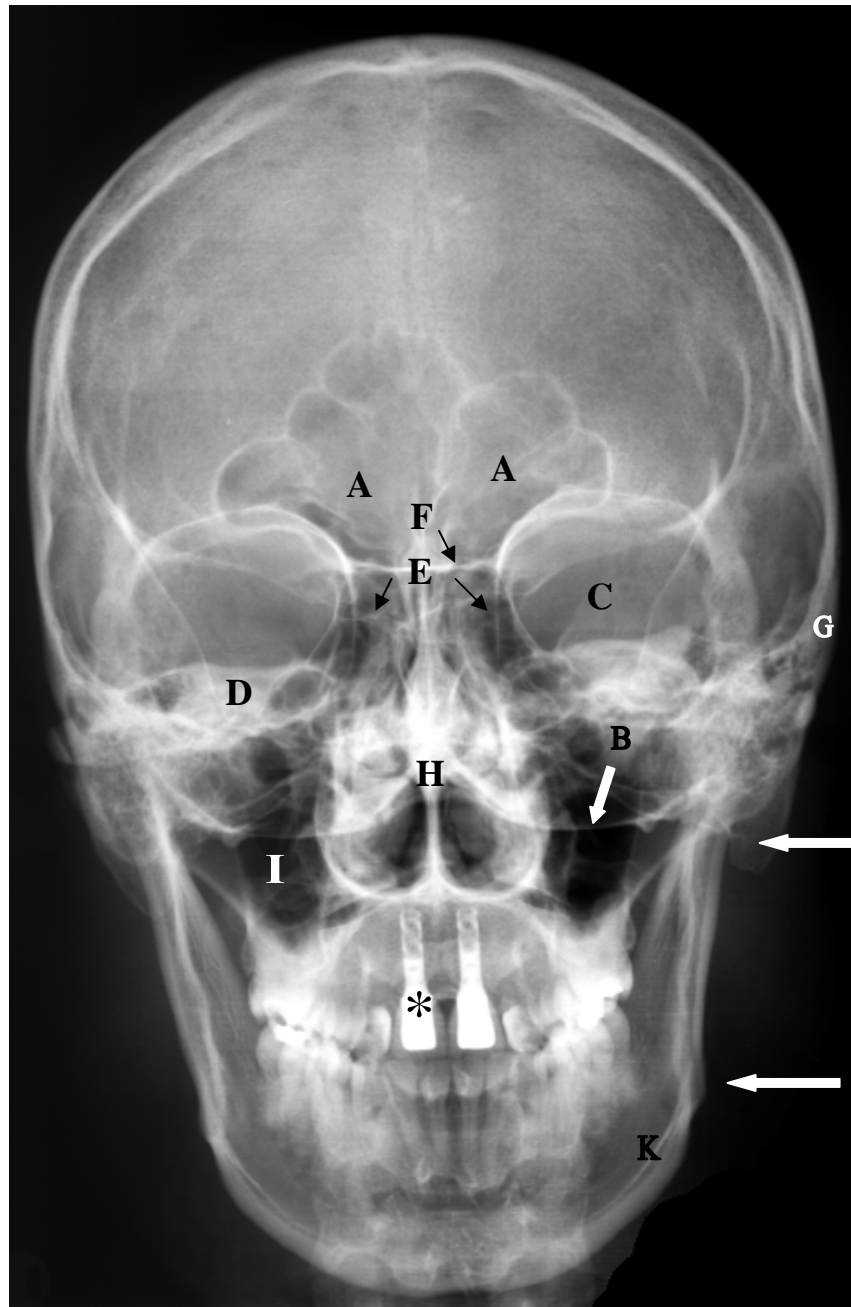


Röntgenaufnahme p.a., Schädel



- A Sinus frontalis
- B Planum nuchale
- C Orbita
- D Pars petrosa
- E Cellulae ethmoidales
- F Planum sphenoidale
- G Arcus zygomaticus
- H Septum nasi
- I Sinus maxillaris
- J Processus mastoideus
- K Mandibula
- L Angulus mandibulae

* Dens incisivus (artificialis)