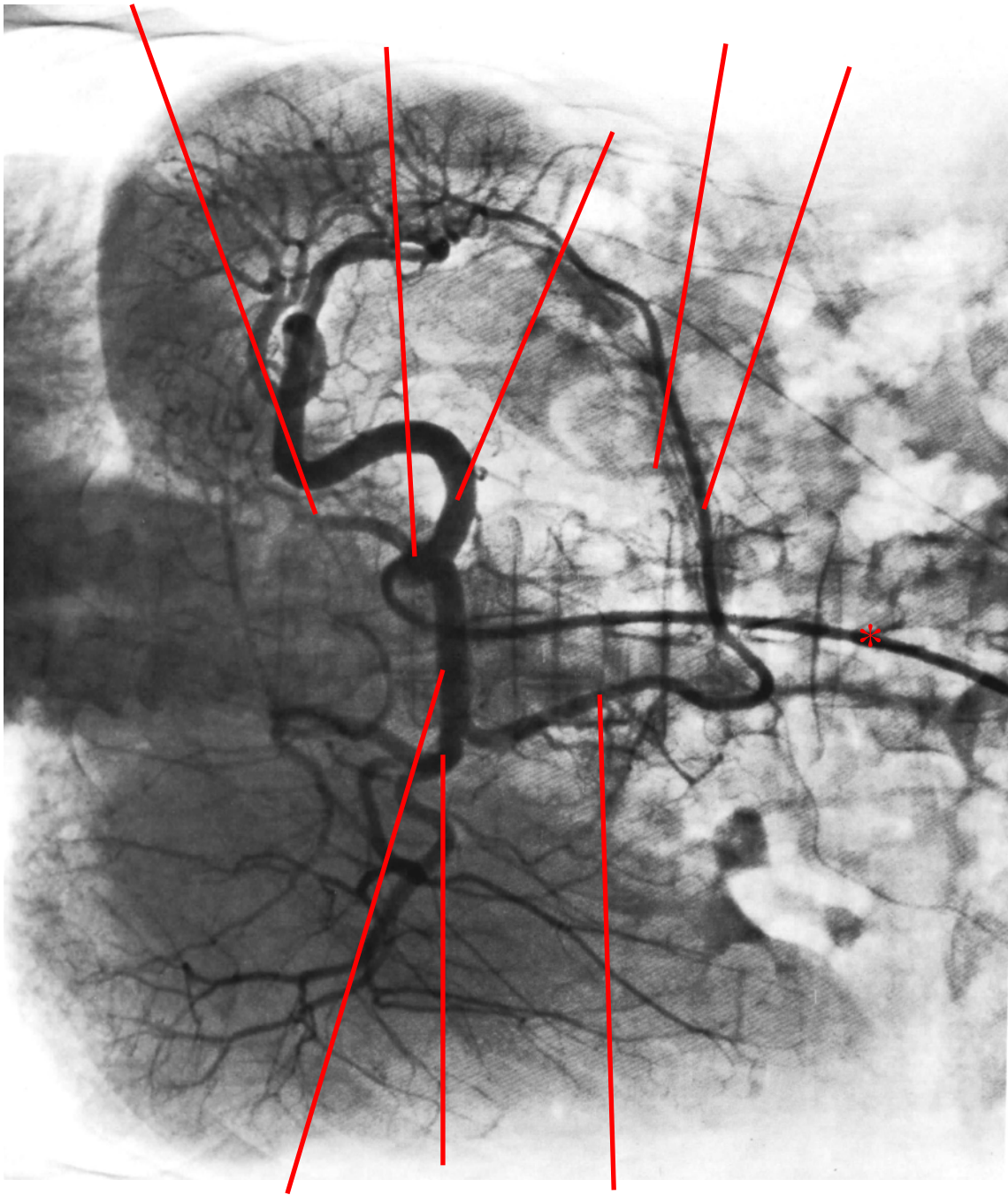


# Angiographie, Truncus coeliacus (Coeliacographie)



\*